

CASE REPORT: NightLase® Procedure – Laser Snoring and Sleep Apnea Reduction Treatment

Jaana Sippus

LaserEdu, Hovioikendenpuistikko 20 B, 65100 Vaasa, Finland

ABSTRACT

Conventional treatments for snoring and sleep apnea have included everything from oral appliances to uvuloplastic operations, radiofrequency tissue ablation, CPAP (Continuous Positive Airway Pressure) masks and alternative medicine. Minimally invasive dentistry, with the use of a laser, now gives us the option for performing non-ablative Er:YAG tightening of the uvula, soft palate and surrounding tissues with a fractional laser handpiece. This treatment, called NightLase®, is provided by Fotona.

This case report describes the treatment of patients with sleep apnea using an Er:YAG laser, with a long-term follow-up from 28-36 months. These clinical cases are part of an uncontrolled study to evaluate the usefulness of the laser in snoring and sleep apnea treatment. Representative case examples following Mallampati classification are included and the benefits of NightLase® therapy over conventional methods will be explained.

Key words: snoring, sleep apnea, Er:YAG laser, NightLase, tightening of uvula, soft palate.

*Article: J. LA&HA, Vol. 2015, OnlineFirst
Received: April 7, 2015; Accepted: May 22, 2015*

© Laser and Health Academy. All rights reserved.
Printed in Europe. www.laserandhealth.com

I. INTRODUCTION

It has been estimated that roughly 30% to 50% of the US population snore and almost 1/3 suffer from sleep apnea. However, only 5% have been diagnosed and treated [1-2].

Snoring and sleep apnea result from obstructed airways. This can be an outcome of many different factors such as anatomic deviations, tumors, polyps, allergy, large adenoids and tonsils, large uvula or a long soft palate [3-6].

Heavy snoring is sometimes called “heroic” snoring and may affect bed partners, causing severe marital conflicts.

Snoring is not sleep apnea and sleep apnea is not snoring. Still, many patients with loud snoring often have obstructive sleep apnea (OSA).

An overnight sleep study known as polysomnography (PSG) should be conducted on severe snorers to conclude if they have OSA. During the sleep test, the number and length of possible apneic periods is recorded, and oxygen levels, heart rhythm (EKG), body position and teeth grinding are examined. Treatment can be discussed after the sleep study results are evaluated.

In obstructive sleep apnea syndrome (OSAS), several breathing pauses may cause a significant decrease in the blood oxygen level and cardiac arrhythmia. OSAS is life threatening [7] with long-term effects resulting in lung and heart problems.

This may also interact with the brain’s restorative REM sleep periods and cause concentration, memory and mood problems. Daytime sleepiness, morning headaches, sexual dysfunction, hallucinations and short-term memory loss are other problems related to OSA [7-9].

- Non-surgical treatment options for patients suffering from OSA include oral appliances, palatal implants, weight loss, alternative medicine and continuous positive airway pressure (CPAP) masks [10].

- Surgical methods include laser-assisted uvulopalatoplasty (LAUP) or uvulopalatopharyngoplasty (UPPP)[11], radiofrequency tissue ablation (RFTVR) and palatal implants [12-14].

a) Laser Treatment Option: NightLase®

There are many benefits of the NightLase® treatment, such as no need for anesthesia, no pain and only three short 20-minute sessions with immediate results.

This case presentation describes the treatment of patients with sleep apnea using an Er:YAG laser, with a long-term follow-up period of 28-36 months. These clinical cases are part of an uncontrolled study to evaluate the usefulness of the laser in snoring and sleep apnea treatment.

II. MATERIALS AND METHODS

Patients with different OSA levels were included in this case report, all from a general dental practice. Ten (10) patients were randomly selected and five (5) typical cases are presented here in pictures – pre-op, post-op and recall. All treatments were performed from late 2011 to the first quarter of 2012. All patients agreed with the treatment protocol using the Er:YAG laser and allowed for the clinical photographs taken pre- and post-op to be used in presentations. Three (3) patients were using a CPAP mask before treatment. No anesthesia was used. Mallampati classification (Fig. 2) was used before and after the treatments.

All treatments were performed with a Fotona LightWalker AT laser (Fotona, Slovenia – also other Fotona models can be used). Before each treatment, the effects of the Er:YAG laser treatment were explained to the patient (Fig. 1a). A fractional laser beam (Fig. 1b) was used with a HP PS04 handpiece at minimally invasive settings according to the manufacturer’s protocol:

- the laser beam is fired at soft intraoral tissue with a repetition rate of 10 Hz in LP mode
- the laser beam is manually delivered across the target, either vertically or horizontally (depending on the region)
- several passes are performed across each region (with well-defined overlap)
- the treated tissue is thermally processed and consequently shrinks
- sessions are scheduled in proper time intervals
- total delivered pulses vary per patient from between 10,000- 15,000.

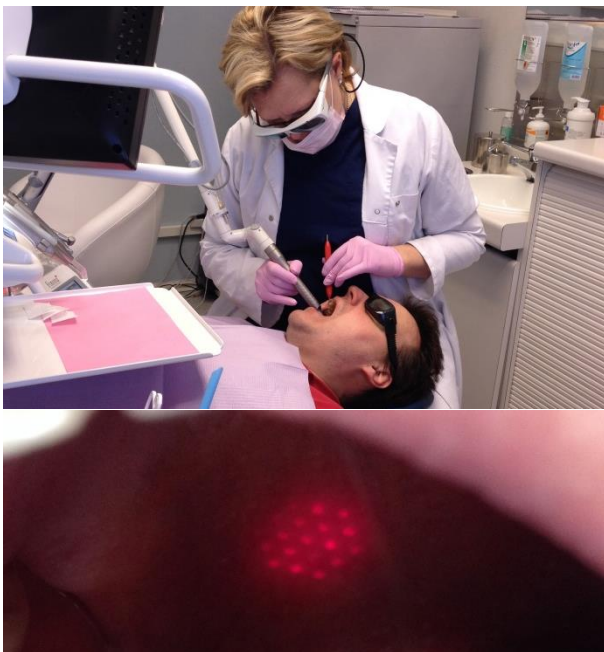
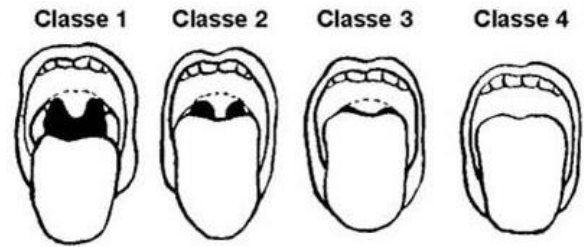

Fig. 1 a, b: Procedure showing NightLase® treatment



- Class 1: Full visibility of tonsils, uvula and soft palate
- Class 2: Visibility of hard and soft palate, upper portion of tonsils and uvula
- Class 3: Soft and hard palate and base of the uvula are visible
- Class 4: Only hard palate visible

Fig. 2: Mallampati classification

a) Clinical Case No. 1

The patient was a 46-year-old female patient. Medical anamnesis revealed severe OSA with related headaches and daytime drowsiness. Intraoral examination showed Mallampati class IV. The result post-op showed class I (Fig. 3).

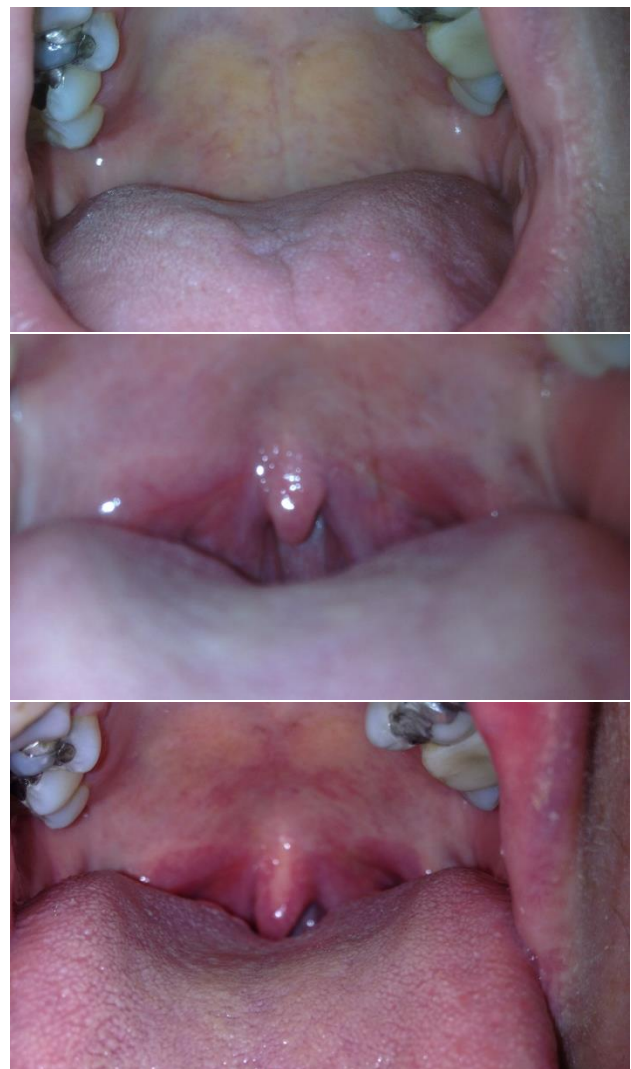

Fig. 3: Patient no. 1 a) pre-op class IV, b) post-op Tx3, class I, c) RC 36 months post-op, class II

b) Clinical Case No. 2

The patient was a 42-year-old female. Medical anamnesis included severe OSA and use of a CPAP mask. The biggest issue for the patient was heavy snoring causing relationship problems. Intraoral examination showed Mallampati class IV. The result post-op was class I (Fig. 4).

c) Clinical Case No. 3

The patient was a 30-year-old male and former ice-hockey player; lately not able to exercise at all – out of breath immediately; severe OSA. He had been using a CPAP mask now for two years with discomfort. Mallampati class IV was reduced post-op to class I (Fig. 5).

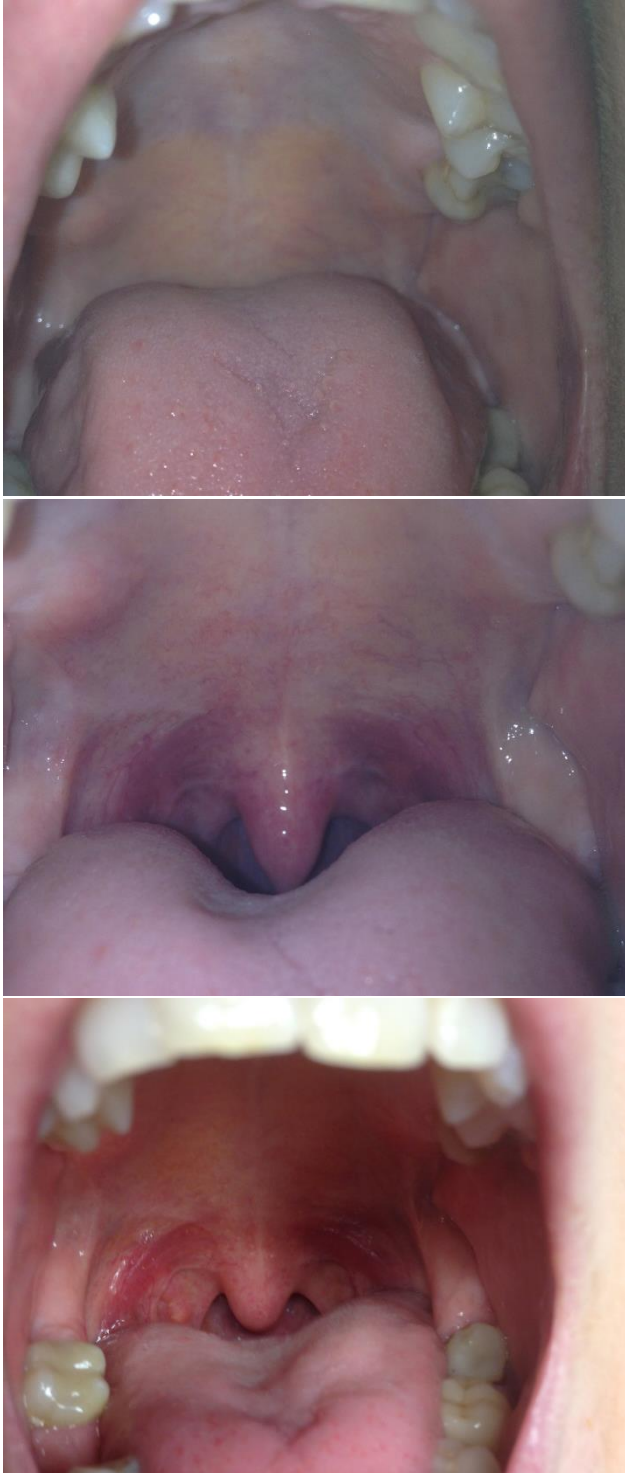

Fig. 5: Patient no. 3 a) pre-op, class IV, b) post-op Tx3, class I, c) RC 36 months post-op, class I

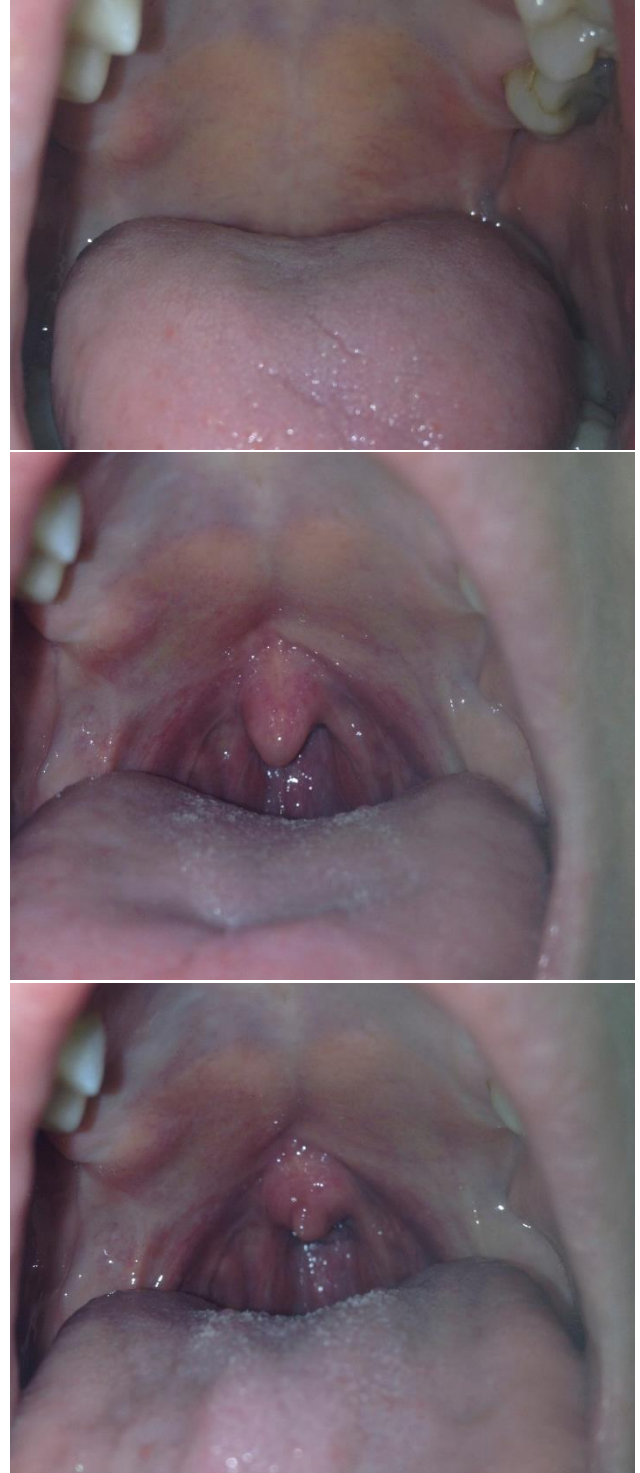

Fig. 5: Patient no. 3 a) pre-op, class IV, b) post-op Tx3, class I, c) RC 36 months post-op, class I

d) Clinical Case No. 4

The patient was a 45-year-old male with snoring and breathing problems causing relationship stress. Mallampati class IV was reduced post-op to class I (Fig. 6).

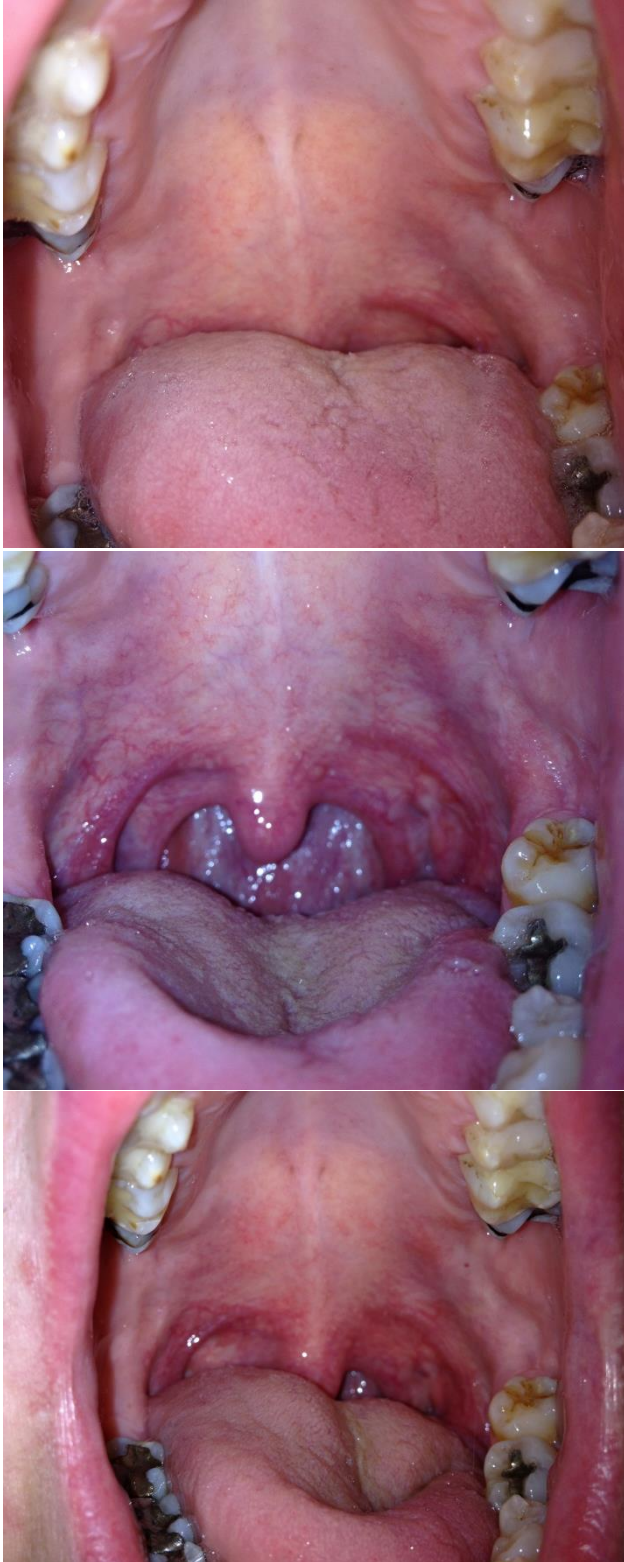


Fig. 6: Patient no. 4 a) pre-op, class IV, b) post-op Tx3, class I, c) RC 28 months post-op, class II

e) Clinical Case No.5

The patient was a 56-year-old male with moderate OSA; relationship problems, sleeping problems, sore throat and morning headaches. Mallampati class IV was reduced post-op to class I (Fig. 7).

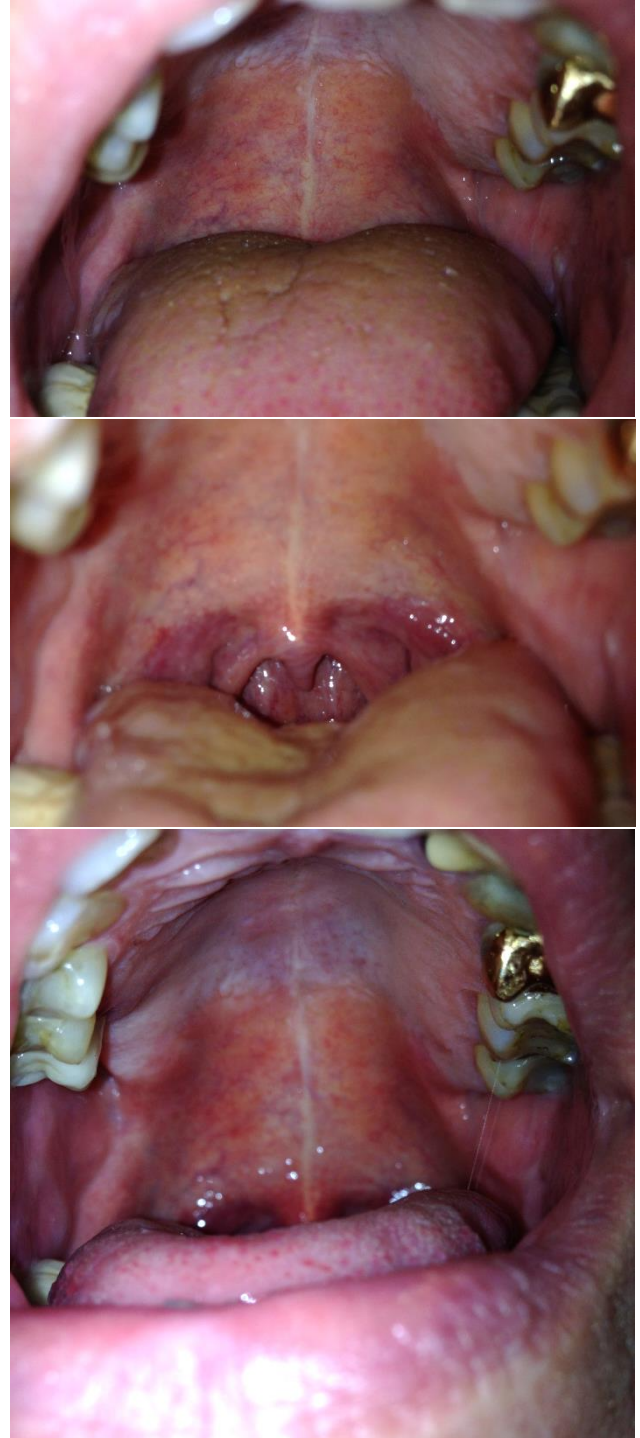


Fig. 7: Patient no. 5 a) pre-op, class IV, b) post-op Tx3, class I, c) RC 36 months post-op, class II

No anesthesia was used during these treatments. All patients using the CPAP mask could discontinue use of the mask after the 1st treatment.

III. RESULTS

After the third treatment, patients reported improvement better than 85%. Average improvement after one treatment session was 51% and after the second session, 61% (see figure 8).

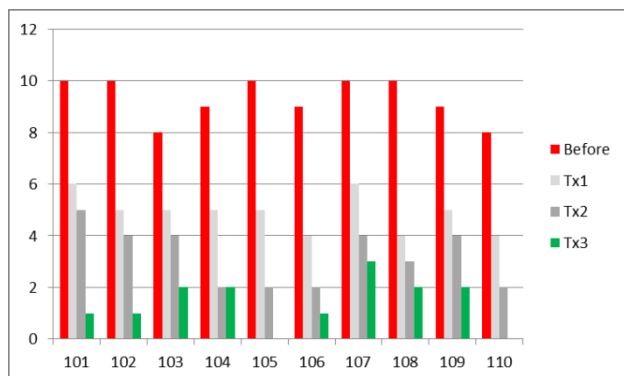


Fig. 7: Total score for snoring reduction: post-op 3 treatments

IV. DISCUSSION

Both snoring and sleep apnea are cause for several health issues and are potentially life-threatening [8]. Still, most patients are unwilling to treat these due to multiple side effects, unsuccessful non-surgical and surgical treatments and uncomfortable procedures [15].

Among other treatments, a minimally invasive laser treatment is now available. In this method, laser light is used for non-ablative thermal heating of the tissue, which subsequently causes shrinking of the collagen fibers. This phenomenon opens up the airways and reduces snoring and sleep apnea.

In these treatments the success rate was over 85% (figure 8). Even after 28-36 months the results were still good. NightLase is an easy treatment to perform, with no pain during or after the treatment. Therefore it can also be repeated with minimum discomfort to the patient. The procedure is safe with no need for anesthesia or medication. Consequently, it produces a good night's sleep and better life quality for the patient and their partner sharing the same bed. However, patient selection with proper examination and exclusion criteria is important to identify the therapy needed.

V. CONCLUSIONS

NightLase® is a safe and very successful treatment for reducing snoring and sleep apnea. It is a minimally invasive treatment with no need for special arrangements, either pre- or post-therapy. Since no anesthesia is needed, the treatment is well accepted by

patients. Long-lasting effects –from one year up to 36 months – allow for high overall satisfaction among patients. NightLase is supported by Evidence Based Dentistry.

REFERENCES

- Jovanovic J. NightLase™ - Laser-Assisted Snoring and Apnea Reduction, 9 Months of Experience (Summary), LA&HA – Journal of Laser and Health Academy Volume 2011, Number 1, Page S11.
- Aston Acton Q. (2013) Anhydrides – Advances in Research and Application, © 2013 by Scholarly Editions TM.
- Arias MA, Garcia-Rio F, Alonso-Fernández A, Mediano O, Martínez I, Villamor J. Obstructive Sleep Apnea syndrome affects left ventricular diastolic function: effects of nasal continuous positive airway pressure in men. *Circulation*. 2005 Jul 19;112(3):375-83.
- Miljeteig H; Hoffstein V, Cole P. The effect of unilateral and bilateral nasal obstruction on snoring and sleep apnea. *Laryngoscope*. 1992 Oct;102(10):1150-2.
- Guilleminault C, Eldridge FL, Tikian A, Simmons FB, Dement WC. Sleep apnea syndrome due to upper airway obstruction: a review of 25 cases. *Arch Intern Med*. 1977 mar; 137(3):296-300.
- Pataka A, Riha RL. Continuous positive airway pressure and cardiovascular events in patients with obstructive sleep apnea. *Curr Cardiol Rep*. 2013 Aug;15(8):385.
- Tamanna S, Gerasi SA. Major sleep disorders among women: (women's health series). *South Med J*. 2013 Aug;106(8):470-8.
- Mannarino MR, Di Filippo F, Pirro M. Obstructive sleep apnea syndrome. *Eur J Intern Med*. 2012 Oct;23(7):586-93.
- Grandner MA, Patel NP, Jean Louis G, Jackson N, Gehrman PR, Perlis ML, Gooneratne NS. Sleep related behaviors and beliefs associated with race/ethnicity in women. *J Natn Med Assoc*. 2013 Spring;105(1):4-15.
- Sullivan CE, Issa FG, Berthon-Jones M, Eves L, Reversal of obstructive sleep apnoea by continuous positive airway pressure applied through the nares. *Lancet*. 1981 Apr. 18;1(8225):862-5.
- Hicklin La, Tostevin P, Dasan S. Retrospective survey of long term results and patient satisfaction with uvulopalatopharyngoplasty for snoring. *J Laryngol Otol*. 2000 Sep;114(9):675-81.
- Krespi YP, Pearlman SJ, Keidar A. Laser assisted uvulopalatoplasty for snoring. *J Otolaryngol*. 1994 Oct;23(5):328-34.
- Simmon FB, Guilleminault C, Miles LE. A surgical Treatment for snoring and Obstructive Sleep Apnea. *West J Med*. 1984 January; 140(1):43-46.
- Coleman SC, Smith TL. Midline radiofrequency tissue reduction of the palate for bothersome snoring and sleep-disordered breathing: A clinical trial. *Otolaryngol Head Neck Surg*. 2000 Sep; 114(9):675-81.
- Lindman R, Bondemark L. *Swed Dent J*. A review of oral devices in the treatment of habitual snoring and obstructive sleep apnoea. 2001;25(1):39-51.

The intent of this Laser and Health Academy publication is to facilitate an exchange of information on the views, research results, and clinical experiences within the medical laser community. The contents of this publication are the sole responsibility of the authors and may not in any circumstances be regarded as official product information by medical equipment manufacturers. When in doubt, please check with the manufacturers about whether a specific product or application has been approved or cleared to be marketed and sold in your country.